



DATE PRESENTING CLINICAL SIGNS

History: Diagnosed with stage B1 degenerative valve disease in May 2021.

12/19/22

ECHOCARDIOGRAPHIC FINDINGS

2D, M-mode, and Doppler study.

PERFORMED BY:

Dana Alterman,
RDCS, LVT

Left atrial size is normal. The mitral valve leaflets are thickened, and there is Doppler evidence of mitral regurgitation present. Left ventricular dimensions are normal. Left ventricular systolic function is hyperdynamic. The aorta and aortic valve appear normal, though trace aortic insufficiency is present. Right atrial and right ventricular dimensions are normal. The tricuspid valve appears normal. The pulmonary artery and pulmonic valve are normal. No shunting lesions are visualized. No heartworms are visualized. No pericardial effusion or cardiac masses are seen.

INTERPRETED BY

Keith Blass, DVM,
MS, DACVIM
(Cardiology)

LA - 30.7 mm
LVIDd - 30.4 mm
LVIDs - 16.0 mm
FS - 47%

PATIENT

LVOT - 1.10 m/s
RVOT - 0.70 m/s

Daisy Zeter

ECHOCARDIOGRAPHIC FINDINGS

A single lead ECG is submitted for review.

SPECIES

HR: 104 bpm
Rhythm: Sinus arrhythmia

Canine

Sinus arrhythmia is present throughout this recording. All complex amplitudes and intervals are within normal limits. No premature beats or conduction blocks are seen.

BREED

Dachshund/Terrier
Mix

ASSESSMENT/RECOMMENDATIONS

Degenerative mitral valve disease

This examination demonstrates no progression of Daisy's mitral valve disease over the past year and a half. As such, her disease still appears to be well-compensated, and Daisy's current risk for the development of clinical signs secondary to it still appears to be low.

SEX

FS No abnormalities are appreciated in Daisy's ECG.

AGE

No therapy is recommended at this stage of Daisy's mitral valve disease.

13 y

A recheck echocardiogram is recommended in 6 months to monitor for disease progression.

WEIGHT

20 lb

HOSPITAL NAME

Eubank AC

REFERRING VET

Dr. Hedberg



DATE

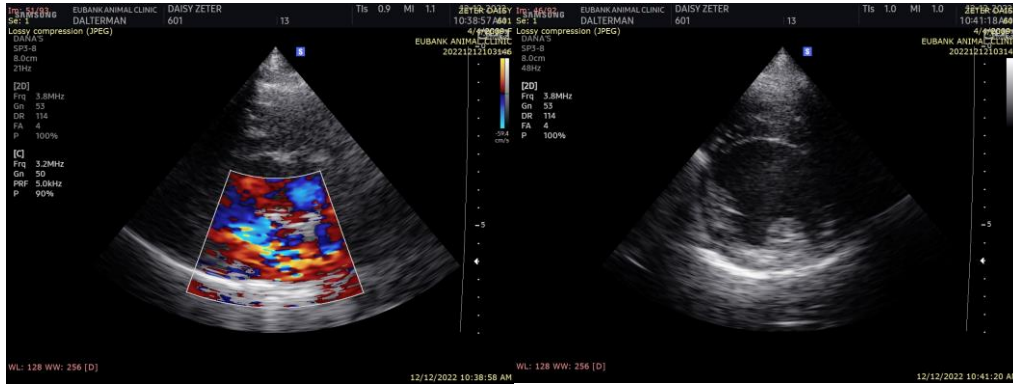
12/19/22

PERFORMED BY:

Dana Alterman,
RDMS, LVT

INTERPRETED BY

Keith Blass, DVM,
MS, DACVIM
(Cardiology)



The information and recommendations provided are based on the images presented by the referring veterinarian. No evaluation can be communicated regarding pathology that was not visible in the image/video clips provided.

PATIENT

Daisy Zeter

Thank you for this referral. If the clinical or image interpretation does not parallel your findings or if I can be of any further assistance please contact me.

SPECIES

Canine

Keith Blass, DVM, MS, DACVIM (Cardiology)
KeithBlass@gmail.com
631-804-5754

BREED

Dachshund/Terrier
Mix

SEX

FS

AGE

13 y

WEIGHT

20 lb

HOSPITAL NAME

Eubank AC

REFERRING VET

Dr. Hedberg